

DRS. CACCHILLO, DANIEL & STANGER

✿ *PROBING THE PRACTICE* ✿



A NOTE FROM THE DOCTORS

WE STRIVE TO PROVIDE CLEAR, DECISIVE, INDIVIDUALIZED TREATMENT PLANS TO ALL OF THE PATIENTS YOU ENTRUST IN OUR CARE. THE LATEST CASE REPORTS IN THIS ISSUE WILL GIVE YOU A LOOK INSIDE OUR DIAGNOSTIC APPROACH TO REDUCING THE AMOUNT OF SURGERY AND TREATMENT TIME FOR DENTAL IMPLANT PLACEMENT WHEN WE CAN.

THANK YOU FOR YOUR CONTINUED REFERRALS TO OUR PRACTICE. WE ENJOY WORKING WITH YOUR OFFICE AND APPRECIATE YOUR CONFIDENCE IN USING OUR PRACTICE FOR YOUR PATIENT'S PERIODONTAL NEEDS.

Dr. David A. Cacchillo

Dr. Terry L. Daniel

Dr. Joelle N. Stanger

MARCH 2021

IN THIS ISSUE

**FREE CE CREDIT:
WHAT ARE THE INDICATIONS
FOR IMMEDIATE IMPLANT
PLACEMENT?**

**IMPLANT MINI-
RESIDENCY SERIES**

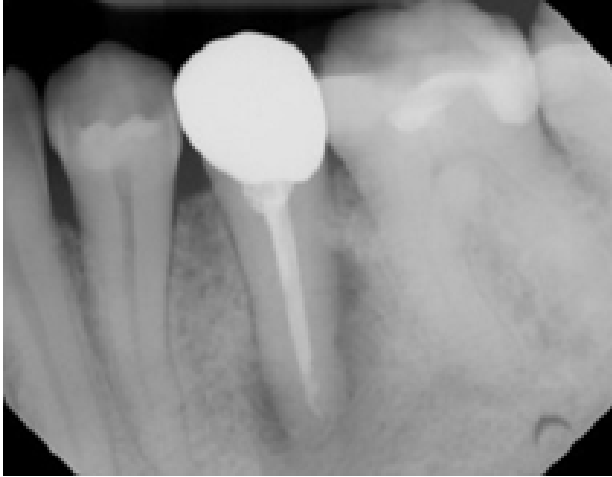**OFFICE
ANNOUNCEMENTS**

COMMUNITY SUPPORT

UPCOMING EVENTS

FREE CE CREDIT:

WHAT ARE THE INDICATIONS FOR IMMEDIATE IMPLANT PLACEMENT?

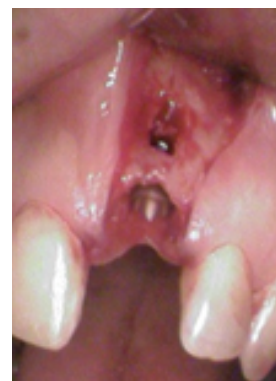
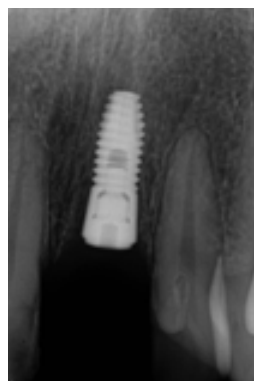
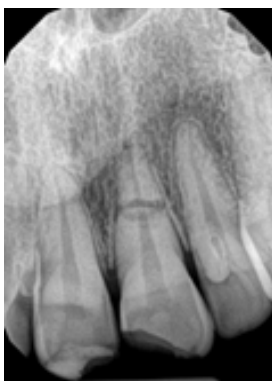Case 1

A 40-year-old female presented to our office with a symptomatic #20. Probe depths range from 3-5mm on #20 with a class 2 mobility. A lingual sinus tract is noted. Upon radiographic evaluation, a radiolucency can be noted lateral and periapical. In this case, we explained to the patient that an immediate implant would not be indicated. The tooth was extracted, cleaned of all infected tissue present, and socket preserved. In 3-4 months from the surgery, the patient will be ready for implant placement in an ideal setting.

Case 2

A 30-year-old female presented to our office with a fractured #9 after a rafting accident. Radiographically a horizontal fracture is noted midroot, but no apical pathology or bone loss present. It was discussed with this patient that ideally an immediate implant could be placed, as long as some of the buccal plate was retained once a gingival flap and extraction was completed. During surgery, a small fenestration was noted on the buccal. Since the majority of the implant would be anchored in bone, with most of the buccal plate intact, an immediate implant was placed. Bone was grafted in the remaining socket and onto the buccal plate. Collagen membrane was placed over the bone and sutured with primary closure.



REVIEW

Immediate implants are great treatment options for our patients. By being able to extract the tooth and place the implant the same day we are saving the patient treatment time (about 3-4 months) and money. At our office, we do our best to place implants immediately, but there are situations where immediate implants would be contraindicated. In cases where we can't place the implant, we always perform socket preservation. Without socket preservation, healing will result in bone loss of 1-2mm of vertical height and 4-5mm of horizontal bone width.

The following are good rules of thumb for indications and contraindications for immediate implant placement.

Indications

- Adequate gingival and bony architecture with the surrounding dentition.
- No trauma effecting bone.
- No purulence or periapical infection.
- Adequate distance from vital structures (ie. IAN, mental foramen, maxillary sinus)

Contraindications

- Active infection
- Lack of bone beyond apex
- Close to vital structures
- Lack of stable occlusion
- No primary stability
- Loss of buccal plate



Last month we celebrated our dental hygienist Lori's 25th anniversary at the practice! She wins over the hearts of all the patients she treats. Thank you Lori for a wonderful 25 years!



CE QUESTIONS

1. How much horizontal width bone resorption happens after extraction without socket preservation?
 - a. 1-2mm
 - b. 2-3mm
 - c. 3-4mm
 - d. 4-5mm
2. Which of the following is a contraindication to immediate implant placement?
 - a. Adequate distance from vital structures.
 - b. Active infection
 - c. No trauma effecting bone
 - d. Bone available beyond the apex
3. What are advantages to immediate implant placement?
 - a. Reduce treatment time.
 - b. Reduce costs for the patient.
 - c. One surgical procedure
 - d. All of the above
4. A patient presents to you with a #18 fractured crown and a periapical radiolucency. They want to get this tooth extracted and have an implant as soon as possible. Is an immediate implant a good option for this patient?
 - a. Yes
 - b. No

References

1. Al-Sabbagh M, Kutkut A. Immediate implant placement surgical techniques for prevention and management of complications. Dent Clin N Am 2015; 59: 73-95.
2. Chrcanovic BR, Albrektsson T, Wennerberg A. Dental implants inserted in fresh extraction sockets versus healed sites: a systematic review and meta-analysis. J Dent 2015; 43:16-41.
3. Schropp L, Isidor F. Timing of implant placement relative to tooth extraction. J Oral Rehabil 2008; 35 Suppl 1: 33-43.



David A. Cacchillo, D.D.S., M.S.
 Terry L. Daniel, D.M.D., M.S.
 Joelle N. Stanger, D.M.D., M.S.

7535 East Main Street • Reynoldsburg, OH 43068 • 614-861-8077 • cdperio.com

Upcoming Events

2021 Implant Mini- Residency Course:

3/19, 5/21, 8/6, 10/22

Periodontal Seminar for the Dental Hygienist:

4/29, 10/21

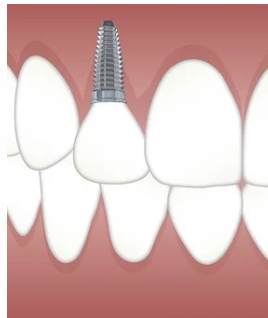
Implant Mini- Residency

OUR 5TH ANNUAL IMPLANT MINI-RESIDENCY SERIES WITH DR. BRADLEY PURCELL STARTS IN MARCH OF 2021

- ENHANCE YOUR SKILLS AND CONFIDENCE IN RESTORING DENTAL IMPLANTS.

- LEARN TIPS AND TRICKS FOR RESTORING SINGLE, MULTIPLE, HYBRID AND DENTURE SUPPORTED IMPLANTS.

- INCREASE PATIENT ACCEPTANCE BY STREAMLINING YOUR PLANNING AND SEQUENCING PROCESSES.



REGISTRATION FOR 2021 IS NOW CLOSED. YOU CAN CALL THE OFFICE AT 614-861-8077 FOR 2022 COURSE INFORMATION AND SIGN UP DETAILS. 35 HOURS OF CE. ALL EXPERIENCE LEVELS WELCOME

FREE CE CREDIT INSIDE!

CE CREDIT RETURN INSTRUCTIONS

1. Read the CE article, record your answers to the 4 questions, and write your name on the blank answer key provided below.
2. Please self check your answers with the key provided.
3. Make a photo copy of this entire page and return to our office via email, fax, or mail.
4. Cacchillo & Daniel, Inc will email your FREE, 1 HOUR CE CERTIFICATE to the office email address.

COMPLETE FOR 1 CREDIT HOUR

NAME: _____

DENTAL OFFICE: _____

1. _____ 2. _____ 3. _____ 4. _____

email: practicerelations@periohealth.org
 fax: 614-861-2554

Completed CE form must be received by course expiration date: 4/9/2021

Answer Key: 1. D 2. B 3. D 4. B

COMMUNITY SUPPORT

REYNOLDSBURG HELPING HANDS FOOD DRIVE

Drs. Cacchillo, Daniel, Stanger and staff are excited to host a canned food drive at this year's Spring Dental Hygiene Seminar! Be sure to start stocking up those donation items for a chance to win prizes at the course. Every 5 items brought in per person will earn you one raffle ticket.

If you are unable to make the event, but would like to participate in our community outreach, please call Amanda to set up item pick up.

