

DRS. CACCHILLO, DANIEL & STANGER

✿ PROBING THE PRACTICE ✿



A NOTE FROM THE DOCTORS

Happy Spring! We were so excited to finally see so many of our referring doctors and staff at the Spring Periodontal Seminar for the Dental Hygienist in April. Last year sure did throw us a curve ball, and we couldn't be more excited to finally gather together for our courses.

This latest newsletter discusses crown lengthening and a gingivectomy. These procedures may take some coordinating with you to discuss the desired cosmetic result and restorative plan. We have resumed lunch meetings in person for those of you that are comfortable doing so, and Zoom consults are always an option if in person meetings cannot take place. Please call us if you have any cases to review, we always look forward to meeting with you whenever necessary. It feels good to be getting back to "normal"!

Dr. David A. Cacchillo

Dr. Terry L. Daniel

Dr. Joelle N. Stanger

MAY 2021

IN THIS ISSUE

**FREE CE CREDIT:
GUMMY SMILE:
GINGIVECTOMY VS.
CROWN LENGTHENING**

**IMPLANT MINI-
RESIDENCY SERIES**

**OFFICE
ANNOUNCEMENTS**

COMMUNITY SUPPORT

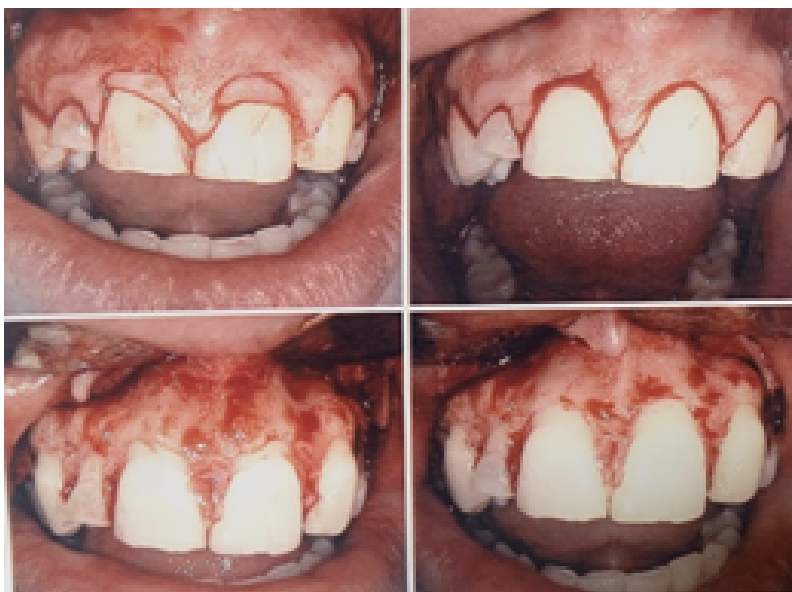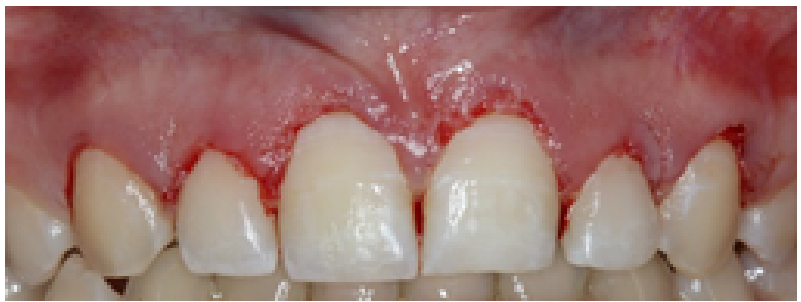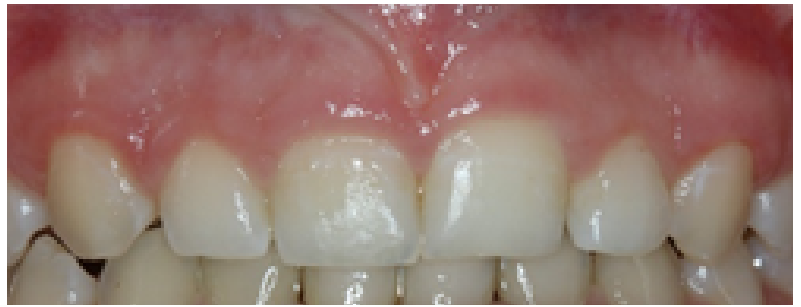UPCOMING EVENTS

FREE CE CREDIT:

GUMMY SMILE: GINGIVECTOMY VS. CROWN LENGTHENING

Case 1

A 16 year old female presented to our office with her chief complaint of “uneven gums and short teeth”. Radiographically, she had approximately 3mm from the bone crest to the CEJ. A gingivectomy was performed.



Case 2

A 45 year old female presents to our office. This patient radiographically had the CEJ right at the bony crest. This is easy to see in the following photos. Both soft and hard tissue was removed to give this patient an esthetic.



REVIEW

When a patient has a “gummy smile”, there can be multiple etiologies as to why this is happening such as: altered passive eruption, vertical maxillary excess, or hypermobile upper lip. Today we are highlighting altered passive eruption cases.

Altered passive eruption is a clinical condition in which the gingival margin is positioned coronally on the anatomic crown due to disorders in eruptive patterns, resulting in short clinical crowns.

There are a few steps in deciding whether a gingivectomy or crown lengthening is needed.

The first step is to discern how much keratinized tissue is present. If there is more than 3mm of keratinized tissue, you will be able to scallop the gingival tissue to the desired level. If there is a thin band of keratinized tissue (<2mm), then you will not be able to do a gingivectomy and an apically positioned flap is indicated. The second component to decide treatment is to look radiographically at where the alveolar crest is. If the bony crest is >2mm from the CEJ of the tooth, then no bone needs to be removed. If the bony crest is closer to the CEJ, then bone needs to be removed to create biologic width and have a long-lasting result. Above is a great chart from Coselet et al in 1977 highlighting these options.

Treatment for the Gummy Smile or Altered Passive Eruption (Coselet et al, 1977)

Classification	Description	Treatment
Type I – Subtype A	MGJ – MGJ apical to the alveolar crest resulting in a wide band of KT (≥ 3mm) Osseous Crest – ≥ 2mm from CEJ	Gingivectomy only
Type I – Subtype B	MGJ – MGJ apical to the alveolar crest resulting in a wide band of KT (>3mm) Osseous Crest – ≤ 2mm or at the CEJ	Gingivectomy or scalloped inverse-beveled flap to the CEJ, repositioned flap with osseous resection to place osseous crest 2mm from CEJ
Type II – Subtype A	MGJ – MGJ coronal to the osseous crest resulting in inadequate or minimal band of KT (≤ 2mm) Osseous Crest – ≥ 2mm from CEJ	Apically positioned flap. No osseous recontouring necessary
Type II – Subtype B	MGJ – MGJ coronal to the osseous crest resulting in inadequate or minimal band of KT (≤ 2mm) Osseous Crest – ≤ 2mm or at the CEJ	Apically positioned flap with osseous resection to place osseous crest 2mm from CEJ

Using the Coselet et al. (1977) rules to determine the appropriate treatment for altered passive eruption.

CE QUESTIONS

1. Which of the following are etiologies for a “gummy smile”?

- a. Altered passive eruption
- b. Vertical maxillary excess
- c. Hypermobile upper lip
- d. All of the above

2. A patient presents to you with limited keratinized tissue and bone directly at the CEJ. What treatment will they likely need?

- a. Apically positioned flap with osseous reduction.
- b. Gingivectomy with osseous reduction
- c. Gingivectomy only
- d. Apically positioned flap only

3. You need greater than ___ keratinized tissue to scallop the gingival margin.

- a. 2mm
- b. 3mm
- c. 4mm
- d. 5mm

4. A patient presents with 7mm of keratinized tissue, and the alveolar crest in 4mm from the CEJ. What treatment will they likely need?

- a. Apically positioned flap with osseous reduction.
- b. Gingivectomy with osseous reduction
- c. Gingivectomy only
- d. Apically positioned flap only

References
 Ribeiro FV, Hirata DY, Reis AF, Santos VR, Miranda TS, Faveri M, Duarte PM. Open-flap versus flapless esthetic crown lengthening: 12-month clinical outcomes of a randomized controlled clinical trial. J Periodontol. 2014
 Coslet JG, Vanarsdall R, Weisgold A. Diagnosis and classification of delayed passive eruption of the dentogingival junction in the adult. The Alpha Omegan. 1977



David A. Cacchillo, D.D.S., M.S.
 Terry L. Daniel, D.M.D., M.S.
 Joelle N. Stanger, D.M.D., M.S.

7535 East Main Street • Reynoldsburg, OH 43068 • 614-861-8077 • cdperio.com

Upcoming Events

2021 Implant Mini- Residency Course:
 5/21, 8/6, 10/22

Periodontal Seminar for the Dental Hygienist:
 10/21

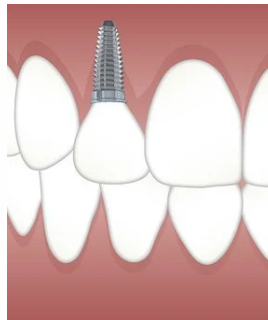
Implant Mini- Residency

**NOW REGISTERING FOR 6TH ANNUAL IMPLANT
 MINI-RESIDENCY
 SERIES WITH DR. BRADLEY PURCELL**

•ENHANCE YOUR SKILLS AND
 CONFIDENCE IN RESTORING
 DENTAL IMPLANTS.

•LEARN TIPS AND TRICKS FOR
 RESTORING SINGLE, MULTIPLE,
 HYBRID AND DENTURE
 SUPPORTED IMPLANTS.

•INCREASE PATIENT ACCEPTANCE
 BY STREAMLINING YOUR
 PLANNING AND SEQUENCING
 PROCESSES.



**CALL THE OFFICE AT 614-861-8077 FOR 2022 COURSE
 INFORMATION AND SIGN UP DETAILS.
 35 HOURS OF CE. ALL EXPERIENCE LEVELS WELCOME**

FREE CE CREDIT INSIDE!

CE CREDIT RETURN INSTRUCTIONS

1. Read the CE article, record your answers to the 4 questions, and write your name on the blank answer key provided below.
2. Please self check your answers with the key provided.
3. Make a photo copy of this entire page and return to our office via email, fax, or mail.
4. Cacchillo & Daniel, Inc will email your FREE, 1 HOUR CE CERTIFICATE to the office email address.

COMPLETE FOR 1 CREDIT HOUR

NAME: _____

DENTAL OFFICE: _____

1. _____ 2. _____ 3. _____ 4. _____

email: practicerelations@periohealth.org
 fax: 614-861-2554

Completed CE form must be received by course
 expiration date: 5/31/2021

Answer Key: ID 2.A 3.B 4.C



COMMUNITY SUPPORT

The Significance of One

Dr. Cacchillo, Dr. Stanger, and our office manager, Amy, along with their spouses, spent a Saturday morning making rice meal packs for a local non-profit organization, The Significance of One in Pickerington, Ohio. Their entire group of over 20 volunteers were able to pack more than 6,000 meals in only one hour! These meals will go directly to The Significance of One schools, students, and their Haitian communities. Please visit <https://www.significanceofone.org/> if you would like to support a non-profit right here in our own community, or ask Amy for more details.